

# Glossopharyngeal schwannoma in childhood

## Case report

J. ALEX THOMAS, M.D.,<sup>1</sup> WILLIAM O. BANK, M.D.,<sup>2</sup> AND JOHN S. MYSEOS, M.D.<sup>3</sup>

<sup>1</sup>Department of Neurosurgery, Georgetown University Hospital, Divisions of <sup>2</sup>Neuroradiology and <sup>3</sup>Neurosurgery, Children's National Medical Center, Washington, DC

Glossopharyngeal (that is, cranial nerve IX) schwannomas are extremely rare nerve sheath tumors that frequently mimic the more common vestibular schwannoma in their clinical as well as radiographic presentation. Although rare in adults, this tumor has not been reported in a child. The authors report the case of a 10-year-old boy who presented with several months of unilateral hearing loss. He was found to have a large right cerebellopontine angle tumor. Given the boy's primary complaint of hearing loss and the appearance of the lesion on imaging, the tumor was initially believed to be a schwannoma of the vestibular nerve. It was found intraoperatively, however, to originate from the glossopharyngeal nerve. To the authors' knowledge, this is the first reported case of a glossopharyngeal schwannoma in a child. (DOI: 10.3171/PED/2008/2/8/130)

**KEY WORDS** • brain tumor • childhood • glossopharyngeal nerve • pediatric neurosurgery • schwannoma

**G**LOSSOPHARYNGEAL (CN IX) schwannomas are extremely rare nerve sheath tumors that frequently mimic the more common vestibular schwannoma in their clinical as well as their radiographic presentation. Although rare in adults, to the our knowledge this tumor has not been reported in a child. We report the case of a child with such a tumor.

### Case Report

*History and Examination.* This 10-year-old previously healthy boy presented with a 3-month history of headaches, nausea, and vomiting, all of which were worse in the morning. He also reported occasional dizziness that did not limit his normal daily activities. Finally, with specific questioning, the patient reported that he had not been able to hear as well from his right ear as from his left. He denied any other neurological symptoms. His mother denied any family history of neurofibromatosis.

On examination, the patient had markedly decreased hearing in his right hear and mild right appendicular ataxia. Otherwise, his neurological examination was unremarkable; his face was symmetric in sensation and motor function, his uvula and tongue were midline, and his gait was normal. There were no signs of neurofibromatosis.

Contrast-enhanced MR imaging and MR angiography of the brain revealed a 4 × 3.5 × 3.5-cm heterogeneously enhancing extraaxial mass in the right CPA (Fig. 1). The mass extended superiorly to the tentorium and inferiorly to the jugular foramen. The mass compressed the right cerebellar hemisphere as well the fourth ventricle and brainstem. There was mild ventriculomegaly. Catheter angiography and subsequent embolization of the lesion were successfully performed 2 days prior to surgery. Finally, an audiological examination prior to surgery confirmed the severely diminished hearing on the right.

*Operation.* The patient underwent a standard right retrosigmoid suboccipital craniotomy in the left park-bench position. Standard intraoperative neuromonitoring was used, and particular attention was paid to CNs VII, VIII, IX, and XII.

After craniotomy and opening of the dura mater, the tumor was located with the assistance of intraoperative ultrasonography. The tumor was then removed in a piecemeal fashion by using the ultrasonic aspirator and sharp dissection. Blood loss was minimal, and the patient required no blood products.

Initially, at the superior aspect of the tumor, the CN VII/VIII complex was identified exiting the IAC. The nerves were stretched and enveloped in the arachnoid of the tumor, but they could be dissected out and spared. Inferiorly, CNs X, XI, and XII were individually identified and dissected from the tumor. Only the glossopharyngeal nerve could not

Abbreviations used in this paper: CN = cranial nerve; CPA = cerebellopontine angle; IAC = internal auditory canal.

## Glossopharyngeal schwannoma in childhood

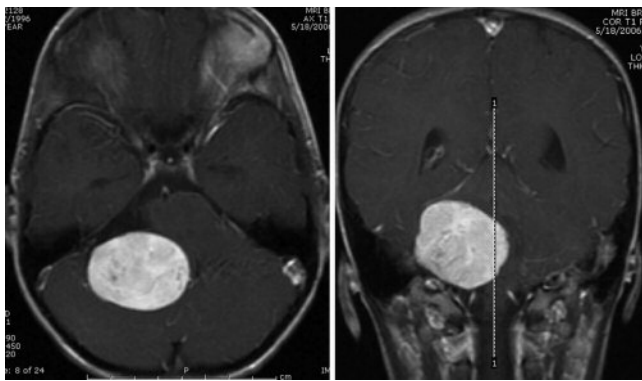


FIG. 1. Preoperative axial (*left*) and coronal (*right*) T1-weighted MR images obtained after contrast administration, revealing a large, heterogeneously enhancing mass in the right CPA with significant mass effect on the brainstem and fourth ventricle.

be immediately identified until the tumor was debulked. After resection of the majority of the tumor, the jugular foramen could be identified, with CNs X and XI converging around the tapered edge of the tumor, identifying CN IX. There was no definitive nerve proximal to the foramen, so the tumor was sharply and completely removed (Fig. 2). During the resection, monitoring revealed activity from CNs VII, VIII, X, XI, and XII, but never CN IX.

**Postoperative Course.** The patient tolerated the procedure extremely well. Postoperatively he had no disconjugate gaze, facial asymmetry, shoulder shrug weakness, or new ataxia. He had no breathing difficulties. His preoperative hearing deficits remained stable postoperatively. He also had moderate hoarseness secondary to right vocal cord paralysis. Finally, although he appeared to have no difficulty eating and drinking after surgery, a modified barium swallow examination showed signs of subclinical aspiration with poor oropharyngeal control. Given this finding, the patient underwent placement of a nasogastric tube at the recommendation of our speech pathologists. He was discharged from the hospital on Day 6 with the nasogastric tube in place and underwent speech and swallowing therapy on an outpatient basis. A repeated swallowing study performed 2 weeks after discharge from the hospital showed significantly improved oropharyngeal function and the nasogastric tube was removed. At 6 months postoperatively, the patient's voice had returned to baseline, his hearing had improved, and he had no swallowing difficulties. The most recent postoperative MR image, obtained 6 months after surgery, showed no recurrent tumor.

### Discussion

Vestibular schwannomas are the most common intracranial schwannomas with an incidence of 1/100,000 persons. Of the nonvestibular schwannomas, trigeminal nerve schwannomas are the most common, comprising 0.8–8% of all intracranial schwannomas and 0.1–0.36% of all intracranial tumors.<sup>8,9,13</sup> Cranial nerve IX schwannomas are an even rarer entity, and only ~40 cases were reported in the literature at the time of this publication.<sup>1–3,5,6,9–12</sup> Most of these tumors present in the 3rd–5th decade of life.<sup>11</sup> The tumors are much more commonly right sided, and there tends to be

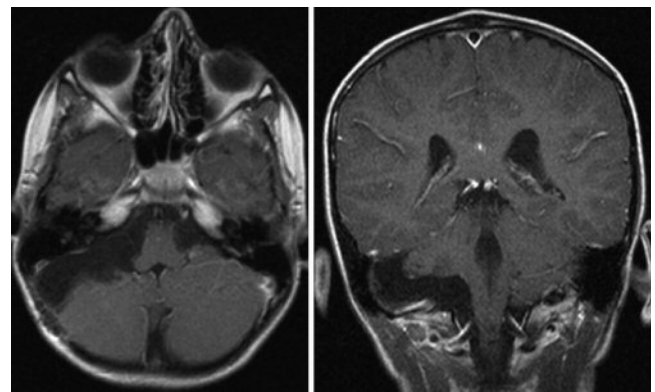


FIG. 2. Postoperative axial (*left*) and coronal (*right*) T1-weighted MR images obtained after contrast administration, revealing no apparent residual tumor and decompression of the brainstem.

a slight male preponderance.<sup>8</sup> To our knowledge, this is the first reported case of a CN IX schwannoma in the pediatric literature.

As with most other cases of CN IX schwannomas in the literature, clinical symptoms and neurological examination of our patient did not help elucidate the correct origin of the tumor. Because of their proximity to the CPA, the jugular foramen, and the several other CNs at these locations, CN IX schwannomas frequently present with symptoms of more common vestibular schwannomas and therefore are misdiagnosed. Indeed, 73–90% of patients with CN IX schwannomas will present with hearing loss as the sole or main neurological sign of the tumor.<sup>8,10</sup> This rate of hearing loss approaches and even exceeds known rates of hearing loss at presentation for vestibular schwannomas of 75–90%.<sup>13</sup> In contrast, in a comprehensive review of previously reported cases, Rapanà et al.,<sup>8</sup> found that 29% of patients with CN IX schwannomas presented with hoarseness and 19% with decreased gag reflex, signs that would more commonly be expected from CN IX dysfunction.

Based on the few case series in the literature most CN IX schwannomas demonstrate involvement of the jugular foramen on radiographs and therefore are classified as one of the jugular foramen schwannomas.<sup>3,9–11</sup> Our patient's tumor corresponds to a Kaye Type A jugular foramen schwannoma in that it was primarily intracranial with minimal invasion of the jugular foramen.<sup>4</sup> As in our case, these Type A schwannomas rarely present with involvement of lower CNs (including CN IX) and therefore are difficult to distinguish from vestibular schwannomas. Indeed, in the series by Kaye et al.,<sup>4</sup> 4 of 6 Type A jugular foramen schwannomas were incorrectly diagnosed as acoustic schwannomas. Sarma et al.<sup>9</sup> compiled a series of 46 consecutively operated nonvestibular schwannomas in adults. Of 10 “jugular foramen” nonvestibular schwannomas in the series, 7 originated from CN IX. Only 1 of these 7, however, presented with signs of CN IX dysfunction; 5 presented with signs of CN VIII involvement.

Several radiographic clues may help differentiate CN IX schwannomas from more common schwannomas of the higher CNs. Computed tomography scanning of the petrous bone commonly shows a widened jugular foramen, eroded jugular tubercle, and normal IAC.<sup>3,10,11</sup> Magnetic resonance imaging of the CPA may be used to visualize higher CNs

coursing separately from the tumor; the mass may also be seen extending away from the IAC inferiorly toward the jugular foramen to proceed extracranially.<sup>10</sup> Ultimately, the origin of the schwannoma may not be known until the time of surgery.

The goal of therapy for CN IX schwannomas should be complete resection as was achieved in our case. Radiosurgery for nonvestibular schwannomas may be a reasonable alternative to microsurgical resection.<sup>7</sup>

Finally, our case illustrates that hearing loss, when the symptom of presentation for patients with CN IX schwannomas, frequently does not improve after resection of the tumor. In a series of 5 patients with CN IX schwannomas by Sweasey et al.,<sup>11</sup> 3 of 4 patients who presented with hearing loss did not have improvement of the deficit postoperatively. None of the 3 patients in the series of Fink et al.<sup>3</sup> had improvement in CN VIII function. Other presenting symptoms such as dysphagia and ataxia can be expected to improve significantly in the follow-up period.<sup>3,10,11</sup>

In conclusion, CN IX schwannomas are extremely rare intracranial tumors, and there are only ~ 40 cases reported in the literature. Because of their proximity to CNs of the CPA and jugular foramen, their presentation can resemble that of more common vestibular schwannomas and therefore lead to misdiagnosis. Gross-total resection is possible in most cases, although transient postoperative deficits are common. Hearing loss, the most common presenting symptom of CN IX schwannomas, may not improve postoperatively.

#### References

1. Andersen T, Ulsoe C, Overgaard J, Ringsted J: Intracranial glossopharyngeal schwannoma, a tumor imitating an acoustic schwannoma. **J Laryngol Otol** **100**:831–835, 1986
2. Claesen P, Plets C, Goffin J, Van den Bergh R, Baert A, Wilms G: The glossopharyngeal neurinoma. **Clin Neurol Neurosurg** **91**: 65–69, 1989

3. Fink LH, Early CB, Bryan RN: Glossopharyngeal schwannomas. **Surg Neurol** **9**:239–245, 1978
4. Kaye AH, Hahn JF, Kinney SE, Hardy RW Jr, Bay JW: Jugular foramen schwannomas. **J Neurosurg** **60**:1045–1053, 1984
5. Mountjoy J, Dolan K, McCabe B: Neurilemmoma of the ninth cranial nerve masquerading as an acoustic neuroma. **Arch Otolaryngol** **100**:65–67, 1974
6. Naunton R, Proctor L, Elpern B: The audiologic signs of ninth nerve neurinoma. **Arch Otolaryngol** **87**:222–227, 1968
7. Pollock BE, Foote RL, Stafford SL: Stereotactic radiosurgery: the preferred management for patients with nonvestibular schwannomas? **Int J Radiat Oncol Biol Phys** **52**:1002–1007, 2002
8. Rapanà A, Lamaida E, Bracale C, Lepore P, Pizza V, Graziussi G: Glossopharyngeal schwannoma, an uncommon posterior fossa tumor: diagnostic and therapeutic aspects: a case report. **Clin Neurol Neurosurg** **99**:196–198, 1997
9. Sarma S, Sekhar LN, Schessel DA: Nonvestibular schwannomas of the brain: a 7-year experience. **Neurosurgery** **50**:437–449, 2002
10. Suzuki F, Handa J, Todo G: Intracranial glossopharyngeal neurinomas. Report of two cases with special emphasis on computed tomography and magnetic resonance imaging findings. **Surg Neurol** **31**:390–394, 1989
11. Sweasey TA, Edelstein SR, Hoff JT: Glossopharyngeal schwannoma: a review of five cases and the literature. **Surg Neurol** **35**: 127–130, 1991
12. Thomsen J: Cerebellopontine angle tumors, other than acoustic neuromas: a report on 34 cases; a presentation of seven bilateral acoustic neuromas. **Acta Otolaryngol** **82**:106–111, 1976
13. Vilela MD, Britz GW, Rostomily RC: Cerebellopontine angle tumors, in Rengachary SS, Ellenbogen RG (eds): **Principles of Neurosurgery**, ed 2. New York: Elsevier Mosby, 2005, pp 521–532

Manuscript submitted October 15, 2007.

Accepted May 5, 2008.

Sources of support: none reported.

Address correspondence to: John S. Myseros, M.D., Division of Neurosurgery, Children's National Medical Center, 111 Michigan Avenue, NW, Washington, DC 20010-2970. email: jmyseros@cnmc.org.